A glossary of CANTIENICA®-evident anatomy

CANTIENICA® Body in Evolution is a training concept based on experiential anatomy. Initiated 1997 by Benita Cantieni, it is continuously being developed to integrate new insights and experiences. Throughout Europe, approximately 2,000 therapists and body workers are currently working with this concept to correct all kinds of postural problems. The "instructions for self-healing" explain in laymen's terms how the human body functions, what the skeletal locomotion system needs, and what makes it ill. Understanding these processes sharpens the awareness for them in the own body, for the own posture, and the everyday movements. As one experiences, feels, and understands how the body works, one becomes able to counteract pain in the joints or problems with the sinews, muscles, or fascia through conscious posture adjustments or invisible movement, making the pain disappear right away.

Living with the CANTIENICA® Method, you understand pain as the body's way of telling you: "I don't like what you're doing there!" And this means that you can take immediate corrective action and right the wrongs done by an awkward movement or a sloppy posture.

The pelvis

Pelvis

The pelvis is both the core and the foundation of an upright human body. It consists of a multiple bone ring and a muscular floor.

Three bones form the bone ring of the pelvis: First, the two hip bones or coxal bones. Each hip bone consists of three bones that are separated at birth but grow together during childhood and adolescence; second, the sacrum, which consists of five vertebrae that have grown together to form a robust bone; third, the tailbone or coccyx. The female pelvis is shorter and broader than the male one and slightly heart-shaped. In an optimal posture, the pelvic bones form a V-shape, like a funnel. The male pelvis in general forms a narrower and higher V.

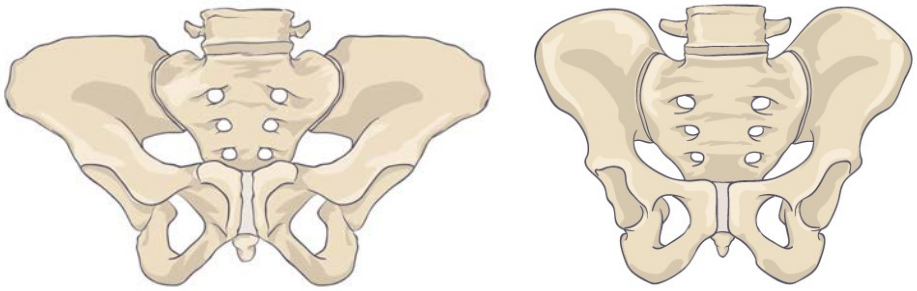

Illustration 1: Pelvic bones (female left, male right)
If the sitting bones are drawn together, the pelvis becomes narrower at the base and wider on top, like a funnel. The pelvis on the left is female, on the right, male.

The focus of the CANTIENICA® Method is on the absolute erectness and alignment of the pelvis. Pelvic posture is key to the correct posture of the entire body. If the pelvis is tilted back or forward even a little, this tilt will continue through the spine and chest. A perfectly aligned pelvis is highly mobile. The two halves of the pelvis (ilia) are hanging vertically on the large surfaces of the sacral joints, attached by an ingenuous system of vertical muscles as well as vertically, diagonally, and horizontally braced tendons. A healthy, mobile pelvis is the prerequisite for healthy sacral and hip joints, a healthy, fully expanded spine, and a weightlessly “hanged” chest. It supports the smooth functioning of all major joints (foot joints, ankle joints, knees, hip joints, sacral joints, vertebral joints, shoulders, joints of the neck and head). Specific, well-aimed exercises mobilize the pelvic joints so that every movement, every step allows for a vertical, rotating movement of the sacral joint.

Pubic bone and pubic symphysis

Os pubis, symphysis pubis

The pubic bone forms the front wall of the pelvic bone structure. It can easily be felt underneath the skin in the pubic area. The bones of the two pelvic halves are not of one piece but are connected through the so-called pubic symphysis. Many CANTIENICA® exercises use the lower edge of the pubic bone as an additional reference point for straightening up the pelvis, usually in combination with the tailbone. This highly detailed work on the bones helps regain the mobility even of seemingly stiff bones.

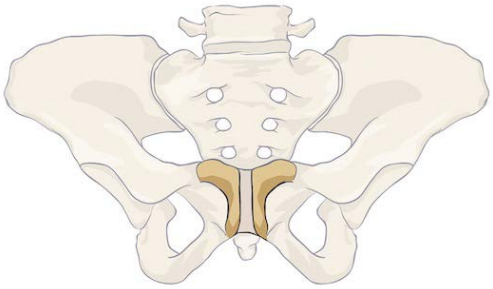

Illustration 2: Pubic bone and pubic symphysis
The pubic symphysis consists of a gelatinous mass between the two bones. It makes the pubic bone flexible and mobile.

Sitting bones

Tuber ischiadicum, os ischium

At the lower rim of the pelvis, the hip bones and sitting bones form two bone circles. The bottom tips of these circles are called ischial tuberosities or sitting bones. You can easily feel them; they're right at the center of the horizontal crease beneath the buttocks. You feel both sitting bones when you sit straight on a hard surface.

There are hip muscles running to this bone circle (pectineus, obturator internus, obturator externus, and quadratus femoris muscles) as well as from the rim of the pelvis to the thigh bones (corpus femoris, piriformis, inferior and superior gemellus, gluteus minimus, and gluteus medius muscles). They connect the hip and thigh muscles.

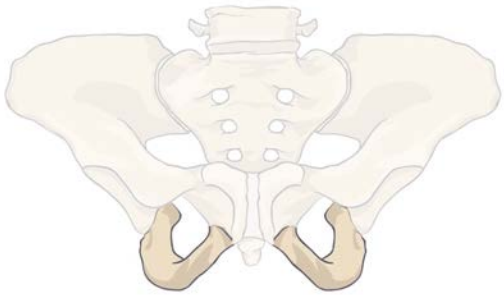

Illustration 3: Sitting bones (also: sitsbones)
These two "semi-circles" at the lower end of the pelvis are called sitting bones. Ideally, the body should align and erect exactly above the center of these sitting bones.

The CANTIENICA® Method uses the sitting bones as reference points for the innermost and largest pelvic floor musculature – the anatomical term for this musculature is levator ani. You can deliberately access this stabilizing "foundation muscle" through the sitting bones – whenever and wherever you like. Each time you deliberately move either one or both of the sitting bones, you activate the related pelvic floor musculature. Once you are confident in using the sitting bones this way, you can engage the levator ani with each step you take and each of the movements, on alternating sides.

Tailbone

Coccyx

The tailbone is the ossified human tail. As we rose up on two feet and had no more need of wagging anything, our bottom five vertebrae grew together to form the tailbone. This tailbone is still mobile; it supports the body's equilibrium along its central axis. The tailbone can be accessed and moved through the pelvic floor musculature and full spinal expansion.

Like the sitting bones and pubic bone, the tailbone is used in CANTIENICA® exercises as a reference point for perfect pelvic posture. This is achieved through the pelvic musculature that supports the bones. The transition to the sacral joint is flexible; with continued training and increased physical awareness, the tailbone will become agile and mobile and join in the vertical pelvic rotations, supporting the fine motor system.

Following new discoveries of Benita Cantieni, the sacrum is counted as the first vertebra, and follows the spine into the upright alignment at all times. This frees the coccyx from pressure from above and makes it more flexible, strengthening the many small muscles surrounding it.

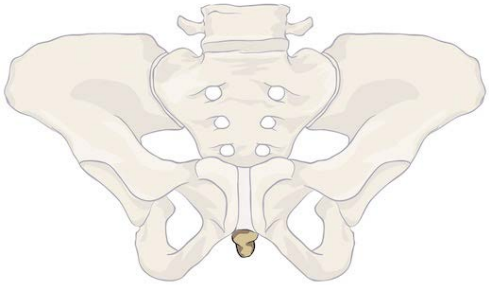

Illustration 4: Tailbone
The "ossified" human tail, the tailbone is connected to the sacrum by a joint and is therefore mobile. It can be aligned downward and moved to the sides.

Pelvic floor musculature, or pelvic diaphragm

Regio perinealis

The pelvic bone structure is held from below by an ingenuously woven muscle bowl. This pelvic floor diaphragm evolved to address the special requirements of humanity's upright gait. The former stomach wall needed to turn into a strong stomach floor. While the shape of human pelvic floor muscles strongly resembles those of other vertebrates, their functions have changed dramatically.

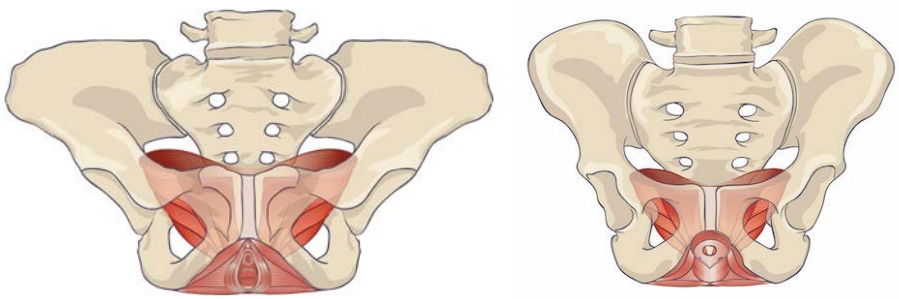

Illustration 5: Pelvic floor musculature (female/male)
The illustration is a realistic – albeit abstracted – representation of the three layers nestled into the lower part of the pelvis (pelvis minor). The innermost layer is the levator ani, the proper bowl of the pelvic floor that contains the pelvic organs. This is what a trained levator ani looks like. If it slackens, it sags.

The three layers of the pelvic floor

The outermost layer

Musculi puboperinealis, bulbospongiosus, sphincter ani externus, ischiocavernosus

The outermost pelvic floor layer is like a loop that envelops the vaginal and urethral opening and anus in women; in men, it surrounds the urethral opening and anus. At the perineum, it is connected to the middle and innermost layers. This is why it gets trained whenever you activate or deliberately relax the larger layers beyond. Overtraining of the outermost layer can lead to vaginal cramps (vaginismus) in women and cause or exacerbated hemorrhoids in both sexes.

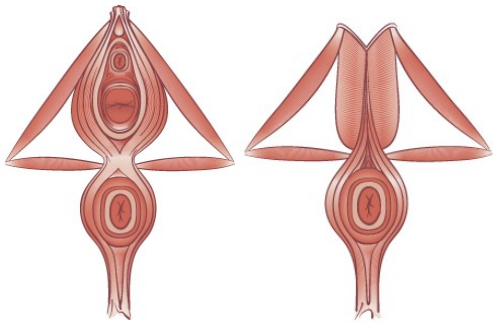

Illustration 6: Outermost pelvic floor layer (female/male)
Female (left) and male (right) erectile and sphincter muscles. The loop surrounding the anus muscles is identical in both sexes. The female sphincter and erectile muscle (bulbospongiosus) surround the vagina, the male muscles surround the penile root. The two horizontal branches are the ischiocavernosus muscles; they support clitoral (women) and penile (men) erection. These sexual muscles form the connection between the outermost loops and the middle layer. A definite mapping is not really possible. The horizontal branch is the superficial transverse perineal muscle. It connects perineum and sitting bones, and you should engage it whenever the instructions direct you to “draw the sitting bones together”.

The middle layer

Musculus transversus perinei profundus, sphincter urethrae externus

The middle layer of the pelvic floor extends from the rim of the pubic bone to the tips of the sitting bones; it forms the frontal wall of the pelvis. At the perineum, it is connected to the outer- and innermost layers.

Illustration 7: Middle pelvic floor layer (female/male)
The middle layer of the pelvic floor is the stomach wall of the upright human body and connects the branches of the pubic bone. It is connected to the outer- and innermost layers at the perineum. At the front, a direct connection to the stomach can be established through the pyramidalis muscle. To th left is the female version with the opening for the vagina and urethral sphincter. To the right the male one with openings for the urethra and the penile arteries

In the female body, the middle layer contains the vaginal vestibule. Overtraining the sphincter muscles usually leads to also overtraining the middle layer. The male middle layer envelops the urethra and penile arteries. The fibers of this middle layer run horizontally from the left to the right branch of the pubic bone. Overly extensive training causes the fibers to distend, and the muscle may shorten in relation to the length of the bone. That would inhibit a clean counter-rotation of the leg musculature and will eventually close down like a vise on the pelvic joints (hip and sacroiliac joints).

When people say that the strongly toned pelvic floor muscles of athletes contribute to problems in vaginal delivery, they are referring to this middle layer. And it is indeed difficult to relax this layer once it's been over trained. You can see this dominance of the middle layer in women with distended adductor muscles: the insides of the thighs are bulging with almost no space between them. This happens because the upper thighs' outward rotation is inhibited, preventing the adductors from expanding. Thus limited and compressed, they bulge.

Men whose middle layer has been excessively trained have deep dents at the sides of their buttocks as well as tightly constricted iliotibial tracts along the sides of their upper thighs.

If the pelvis is perfectly aligned and straightened as intended by its vivatomy, this middle layer is easy to detect and engage. Full expansion and a neutral pelvic posture without any forward or backward tilts are key. Trained in suitable moderation and only in connection with the levator ani, the middle layer of the pelvic floor plays an important part in stabilizing the pelvis. It also protects the hip joints by keeping the lower pelvic rim narrow for a V-shaped pelvis. This optimal position ensures that all the joints enjoy lifelong mobility.

An indicator for a middle layer trained in "suitable moderation" is a straight and slim gracilis muscle. If you can see through the space between the upper thighs as you are standing nicely aligned and erect, the middle layer is not overtrained. The sartorial muscle will then also be able to develop perfectly. It is responsible for stabilizing the relational position of upper and lower leg, and it supports the anatomically correct alignment of the pelvis. Whenever the instructions ask you to "rotate the upper thigh muscles outward from the groin," the sartorial muscle is involved.

The innermost layer

Musculi puborectalis, pubococcygeus, coccygeus, iliococcygeus (levator ani), obturatorius internus

The innermost or central layer of the pelvic floor is the one with the largest surface area. It is spread like a fan from the sacrum to the outer rims of the pelvic bones (iliums) and to the pubic bone in front. The levator ani ("anus lifter") forms one part of this central layer. If the levator ani is strong and well-exercised, it supports the organs in the lower abdomen, and notably the bowel, like a bowl. If it slackens, it sags.

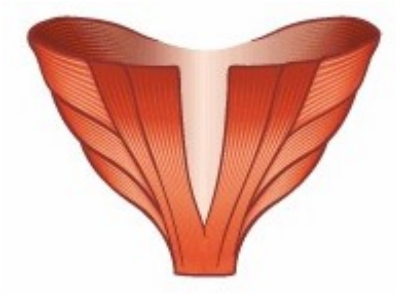

Illustration 8: Levator ani (schematic drawing)
The drawing illustrates the levator ani's effect and function as a "muscle bowl" in the pelvis minor. Numerous tendons attach it directly to the bones in front and at the sides as well as to the sacrum. It is this net of direct connections that enables us to control our pelvic joints and spinal expansion through the levator ani.

At the perineum, this innermost – and, according to our current insight, most important – pelvic floor layer is connected to the middle and outermost layers. Its stem or neck lies underneath the anal sphincter. If the pelvis is properly aligned in a V shape (narrow at the bottom and widening toward the top), the levator ani is stretched out like a safety sheet: it gets pulled tight and upwards into the body cavity. As a result, the muscles are strengthened, and the organs in the lower abdomen are lifted up into the abdomen. As the top rim of the pelvis widens, it creates more space for all organs.

The better developed the levator ani, the more pronounced its muscle neck. In women, this neck runs symmetrically with the vagina and can "lengthen" it if trained anatomically well. The vagina thus grows slimmer – lengthened only by the levator ani neck, without any need to over train the vaginal erectile and sphincter muscles.

The structure of the innermost pelvic floor layer is symmetric. Its left and right sides can be activated and engaged independently. It responds to every movement by the two pelvic halves and does therefore play a key part in pelvic-friendly walking.

If the levator ani performs its demanding duties, the bladder, too, can return to its proper place. To cure incontinence (the involuntary release of urine or stool) permanently, any weight that presses down on the organs must be lifted. In order to cure incontinence, you will therefore almost certainly need to work intensely on expanding the torso and learn to use the diaphragm correctly for breathing. If you lose urine when you laugh, cough, or sneeze, it isn't because the bladder is too weak but because the sudden pressure increase caused by laughing, coughing, or sneezing causes the diaphragm to bang down on the bladder with immense force. Prevent this downward shock, and the bladder will be fine. See also "Diaphragm".

Hip muscles

Musculi gluteus minimus, piriformis, gemellus superior, obturator internus, gemellus inferior, quadratus femoris, psoas major, psoas minor, iliopsoas

The hip muscles are connected to the pelvis and pelvic floor muscles through bones, tendons, and ligaments. In an vivatomically sound leg axis with counter-rotating upper and lower leg muscles, the hip muscles are strong and supple; they protect the sacral and hip joints (iliosacral articulation and coxal articulation).

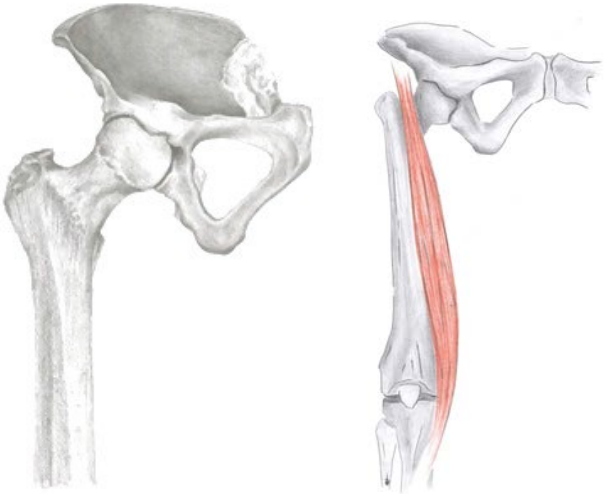

Illustration 9: Hip joint
To the left, we see the femoral head standing perfectly in its socket. To the right, the Sartorius muscle.

Pyramidalis muscle

Musculus pyramidalis

Pyramid-shaped as the name suggests, the pyramidalis muscle starts at the top edge of the pubic bone and ends in a pyramid peak about a small hand's width above the pubic bone. This small muscle links and connects the pelvic floor musculature to the frontal stomach wall musculature (transversus abdominis, abdominal external oblique, and rectus abdominis muscles). It plays a prominent part in erecting and aligning the pelvis. Conventional pelvic floor and posture trainings underestimate the connective power of the pyramidalis – in most cases, it isn't even mentioned. The CANTIENICA® Method employs the pyramidalis muscle as a mediator between pelvic floor and the abdominal muscles. In some Caesarian section techniques, the cut goes right through the pyramidalis muscle, which is why many women complain of a belly overhang as an aftereffect. Re-establishing and strengthening the connective network of the pyramidalis tones this belly; the scar becomes more supple, and the branches of the pudendal nerve receive "unspecific stimulation" and are encouraged to grow again.

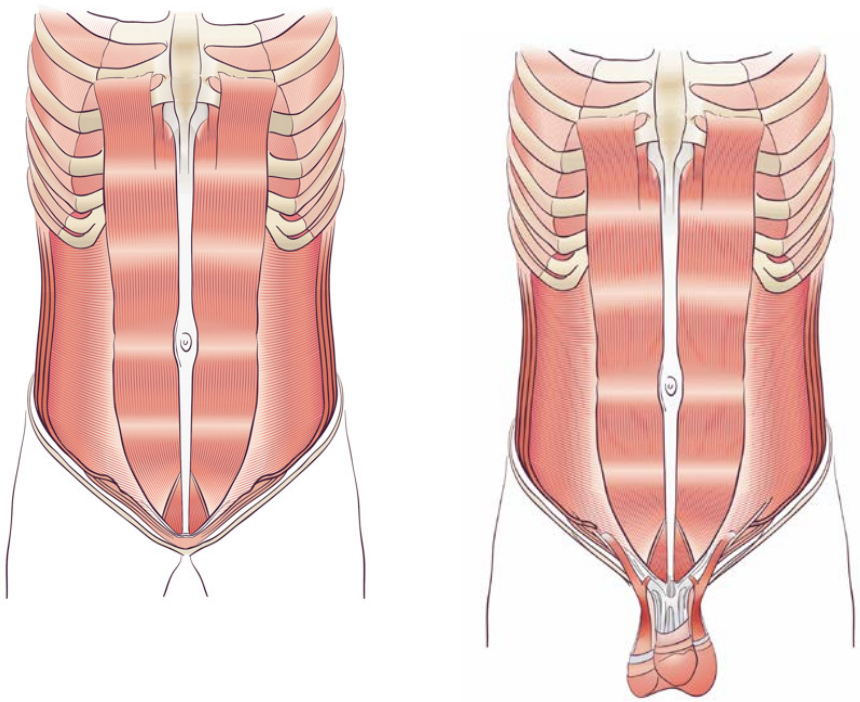

Illustration 10: Pyramidalis muscle (female/male)
Considered a useless evolutionary remnant by conventional anatomists, the pyramidalis muscle is used by the CANTIENICA® Method as a link between pelvic floor and abdomen. Trained properly, it prevents the belly overhang that is often an aftereffect of Caesarian sections and abdominal surgery. In addition, it stimulates the pudendal nerve and enhances pelvic floor sensitivity – also during sex. In the male body, the skin connects the testicles directly to the transversus abdominis and pyramidalis muscles.

Back

Interconnecting network of the deep musculature

In the back, the innermost pelvic floor layer connects to the multifidus muscle (which means “muscle split into many parts”) and the iliocostalis muscle. These two, in turn, are linked directly to the so-called autochthonous back musculature, an intricate system of more than 200 small muscles that protect and support each vertebra of the spine vertically, horizontally, and diagonally, making the spine mobile.

The diaphragm, too, is used to create full expansion by engaging all vertical structures in its radial widening. The diaphragmatic crura and lumbar part of the diaphragm form a “loop” (hiatus) that surrounds the opening for the aorta, and is connected through muscle and tendon branches along the spine. This loop can be considered the deepest part of the back musculature. Its loop-like expansion supports the mobility of the thoracic spine. Its branches form a stabilizing connection to the lumbar spine.

At the abdominal level, the perfect alignment of the pelvis perfectly engages and makes use of the so-called deep abdominal muscles, i.e., the psoas major and iliacus muscles. The pyramidalis muscle connects the pelvic floor to the external abdominal muscles at the front of the abdominal wall. Underneath the buttock muscles or glutes (gluteus maximus, medius, and minimus muscles), the human body features a set of power muscles that can be activated and engaged via the pelvic floor. These are the obturator externus and internus muscles, the gemellus muscles (inferior and superior), the literally pear-shaped piriformis, and the quadrilateral quadratus lumborum muscle. The hip muscles, in turn, are connected closely to the upper thigh musculature (sartorial muscle; hamstrings: biceps femoris, semimembranosus and semitendinosus muscles and tensor fasciae latae muscle). With each pelvic-floor-controlled step, these muscles are engaged and “taken along” via the hip muscles.

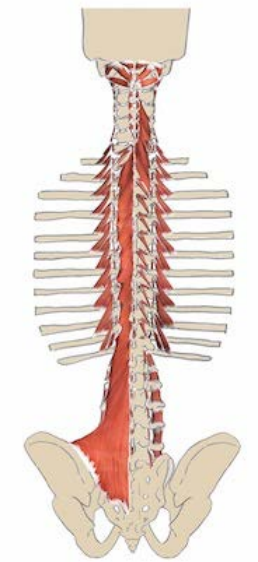

Illustration 11: The Multifidus
The Multifidus Muscles provide mobility and stability at the same time: They enable the vertical movements in the pelvis halves, that are so essential to the CANTIENICA®-Method. At the top of the vertebra the little individual Multifidus muscles cross the midline and enable the atlas and the skull to react in a crossover action.

Spine, 24/7 expansion

Normally – and there are more exceptions than one would think – the spine is made up of 24 vertebrae: 7 cervical vertebrae (vertebrae of the neck), 12 thoracic vertebrae (vertebrae of the chest), and 5 lumbar vertebrae. That's the official count. CANTIENICA®-Vivatomy starts at the bottom and works the spine upwards: sacrum, 5 lumbar vertebrae, 12 thoracic vertebrae, 7 cervical vertebrae. Stacked up like building blocks, these bones by themselves would form a rather helpless construction. Its strength, flexibility, and erectness comes from the so-called autochthonous musculature, a complex system of more than 200 small muscles. They protect and support the vertebrae from and to all sides, left and right, above and below. On the sides, each single thoracic vertebra is also braced diagonally against its neighbors. Like our pelvic floor musculature, we tend to neglect our autochthonous back musculature in daily life. Conventional fitness training usually only addresses the peripheral muscles that can be seen and felt from the outside. Hardly ever does the deep musculature get the attention it deserves, even though it is vital for a healthy, robust skeleton.

Stretching and expansion require tension from two poles. The pelvic with an actively engaged levator ani forms the low pole for a full expansion of the spine. The high pole is the crown of the head.

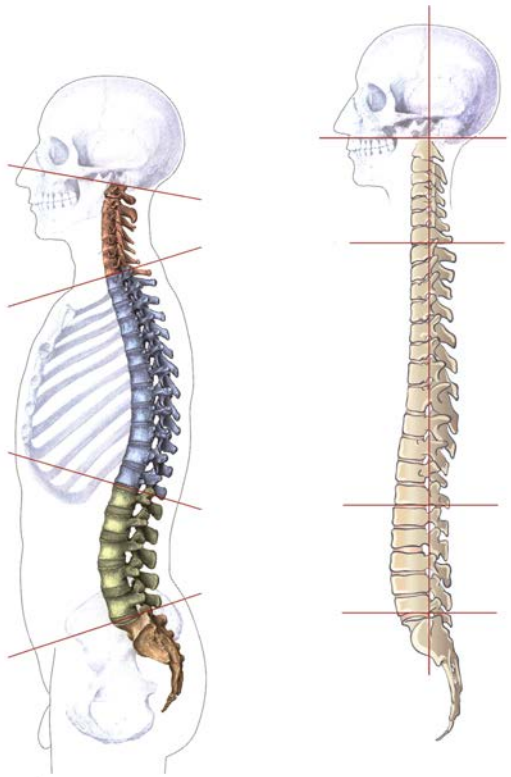

Illustration 12: Spine in erect alignment
In the CANTIENICA® body concept, the spinal canal is straight. As a result, the spine shows no double-S-shaped curvature. The slight curvature at the lower back is due to the shape of the vertebral processes. The processes of the lowest thoracic vertebrae are much smaller than the processes of the adjoining lumbar vertebrae. That's why there must be enough space behind the lowest thoracic vertebra for a butterfly to live comfortably. When you press the back flat, the spinal cord isn't straight any more, and the pressure of the vertebrae shifts the pelvis and chest from their proper alignment.

Autochthonous back musculature

A complex of approximately 200 small muscles subdivided into spinal system, intertransverse system, and transversospinal system (*interspinales lumborum*, *intertransversarii mediales lumborum*, *intertransversarii lateralis lumborum*, *levatores costarum breves*, *levatores costarum longi*, *spinalis thoracis*, *rotatores thoracis breves*, *rotatores thoracis longi*, and *spinalis cervicis* muscles).

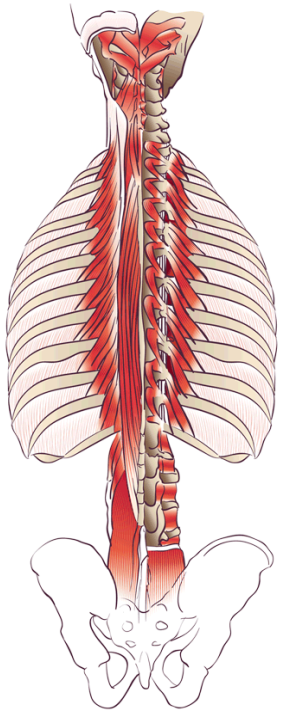

Illustration 13: Autochthonous back musculature
Here it is, the muscle miracle deep within the back. More than 200 small muscles that give the spine the gifts of hold and elongation (lumbar spine) as well as enormous mobility (thoracic spine). The lumbar vertebrae are linked by strong vertical connectors, the thoracic vertebrae (which are able to rotate) also feature diagonal and transversal braces. Contrary to traditional opinion, we teach that this muscle system may be deliberately exercised and engaged (which would make it autonomous rather than autochthonous). The multifidus runs above the autochthonous vertebral muscles; you could say that it connects the levator ani directly to the muscles that bear the head.

These autochthonous muscles protect and stabilize the fully expanded, erect spine from every direction: to the sides, diagonally, downward, and upward – with the exception of the lumbar spine, which is only braced vertically. The multifidus (i.e. “split into many parts”) muscle interlinks the spinal and pelvic musculatures. At the back of the neck the autochthonous muscles are connected to the muscles that support and move the head. In a slumped, rounded, flaccid posture, the autochthonous musculature is inactive. Conventional strength training that addresses the outer musculature also fails to reach the autochthonous musculature, allowing it to atrophy instead. When this happens we shrink. Our spinal discs are compressed. Nerve openings narrow and calcify. Our vertebrae are damaged. Our bone density decreases. Our joints wear out.

Since so many people suffer from the same symptoms, it was long believed that the autochthonous musculature couldn’t be controlled deliberately. Yet the opposite is true: each time you actively expand the body according to the blueprint, you’re activating the large complex of autochthonous muscles deep inside the back. And you thus prevent shrinking in old age, because the shrinking process always starts with a slackened autochthonous skeletal musculature. Gravity is not to blame!

Crown of the head, head up

If the torso is fully erect and expanded, the head will balance perfectly on the cervical vertebrae (axis, atlas). Together, the deep neck muscles (longus capitis, longus colli, and interspinales cervicis muscles) and the muscles that hold the head (rectus capitis posterior, obliquus capitis, semispinalis capitis, and other muscles) bear the weight of the head – over 13 pounds. The joints between axis/atlas and the skull are self-supporting. The occipital condyles (oval facets of the occipital bone) and foramen magnum (a large opening through which the extension of the spinal cord enters the skull) are particularly movable: they can move smoothly and softly up and down, to the sides, back and forth, and even diagonally. If the scull is in the perfect position, the entire facial mimetic musculature benefits, this muscles too, can be interlinked and expanded.

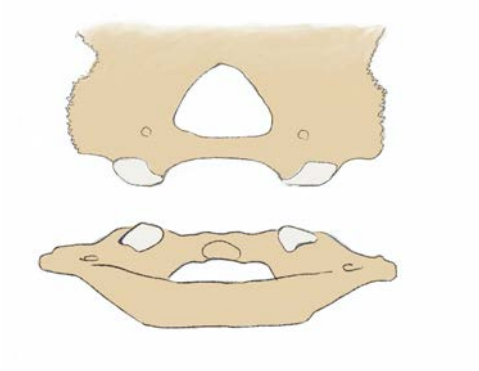

Illustration 14: Atlas
The skull meets the topmost vertebra (called atlas) in an ellipsoid joint. If the body is fully erect and expanded – i.e., if the muscle structures at the front and back are of equal length and support one another – this ellipsoid joint features a joint cavity (intra-articular space) that allows the head great freedom of movement. When you follow the instruction "draw the crown of the head upward to the ceiling," you engage these joints.

The human vertebrate is fully and perfectly expanded, if the torso is drawn in two directions. Pubic and tailbone are facing downward, the sacrum stretching into the opposite direction, together with the vertebrae; the crown and peak of the head, upward. This pull and counterpull extension causes the entire musculature to interconnect perfectly. If you stretch only the bottom of the spine downward, you gain nothing – in fact, you'll probably slump. If you only stretch the crown of the head up to the sky, on the other hand, you will most likely pull up the shoulders, becoming – and looking – tensed up. Only the pull and counterpull in two directions will make the body – and you – toned, vibrant, energetic, responsive, awake, and radiant. It will double the body's strength as all muscle connections are perfectly engaged.

In the CANTIENICA® system, the crown of the head is that most sensitive place at the top of the head about four fingers width behind the center of the skull roof where an imaginary extension of the spinal cord would emerge when you're standing fully aligned, erect, and expanded. (The more this crown of the skull is exercised, the bigger the area will be felt. The most common reaction reported is a tingling sensation.)

Supporting the head: atlas and axis

Atlas and axis are mainly responsible for the head's mobility. The head, which weighs on average around 13 pounds, largely supports itself. If the head is set down upon the atlas – which seems to be the unfortunate norm – the chest tries to evade this pressure; some neck muscles get hyperextended (scalene, sternocleidomastoid, splenius capitis, thyrohyoid, sternohyoid, etc.) while others are shortened (external and internal intercostal, subcostal, and transversus thoracis muscles); the ribs and collarbones may shorten; the diaphragm is chronically pushed down. All this can lead to tension headache, migraines, difficulties swallowing, teeth grinding (bruxism), and spinal deformations.

The atlas is the topmost vertebra of the spine. Technically – or anatomically – it is apart of a joint: the joint of the head. Through the foramen magnum it connects the skull and the axis. The axis is the second vertebra of the neck (below the atlas). It secures the atlas and helps the head twist and turn.

Aligning the chest

As above, so below: if the upper body sags, the pelvis will tilt – and vice versa. Shoulder problems almost always coincide with a sunken or puffed-up chest. The sternum sinks downward and, over time, shortens. The ribs are pulled downward; the intercostal muscles between the ribs slacken.

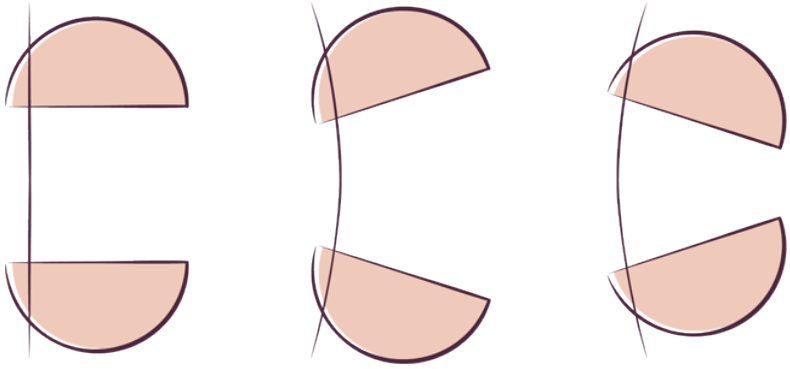

Illustration 15: As above (chest), so below (pelvis)
Left side: Pelvis and chest in congruent alignment.

Center: the pelvis is tilted backwards from the sitting bones; consequently, the chest also tilts back. This results in saddle back (lordosis); the ribs stick out.

Right side: the pelvis tilts forward; the chest counters the movement and also hunches forward. The back is rounded; the stomach hangs down and slackens.

This downward pull shortens the collarbones (clavicles), which drag down the acromia (the "roofs" over the shoulder joints) and shoulder blades (scapulae). The entire throat and neck musculature slackens and shortens (sternocleidomastoideus, pectoralis major and minor, serratus, teres major and minor, subscapulis, etc.) In turn, the muscles in the back of the neck and upper back are hyperextended and overstrained, which leads to chronic tension in the neck and back and consequently, to tension headaches or migraine.

The CANTIENICA® Method teaches you to stretch the chest upward and away from the pelvis and to align it fully erect so that the ribs are horizontally straight. The collarbones should be long and straight; the superior border of the shoulder blades should be straight and lie against the back below the highest rib. Initially, all this may require a bit of imagination, but once you understand and apply the concepts, the free-floating chest will give you a wonderful feeling of lightness that will spread upward as well as down.

Diaphragm (thoracic)

Diaphragma

The diaphragm stretches across the inside of the ribcage like a dome. It is a highly flexible, elastic sheet of muscle and tendons. When we breathe, this muscle-tendon sheet moves and extends the ribs so that the lungs can fill with air and increase in volume.

Illustration 16: The diaphragm viewed from below
At the periphery of this image we see the longitudinal muscles; the white center is the sheet of tendons. When the body expands and stretches out lengthwise during inhaling, the muscles at the sides draw the bottom ribs together – this effect is similar to that of the levator ani drawing together the sitting bones. The top of the diaphragm becomes wide like a parachute or paraglider, the chest expands, as does the visceral pleura, and the breath can fill the entire lungs, all the way to the top loabs of the lungs. – The small round hole on the illustration left of the vertebra is for the veign, called vena cava. Through the loop runs the esophagus (hiatus oesophagus), and at the bottom of that loop is another loop, the opening for the aorta (hiatus aorticus).

In the CANTIENICA® Method, the diaphragm expands radially (upwards as well as elliptically to all sides) like a dome. The lowest, floating ribs are drawn inwards, expanding the inner cavity for the higher ribs. The expansion in all directions increases the volume of the chest cavity immensely. The organs located above the diaphragm are continuously massaged by the steady alteration of expansion and release. The organs below are protected while also enjoying a “breath massage” through the fully expanded, stretched torso musculature as it gently contracts and relaxes with the rhythm of the breath.

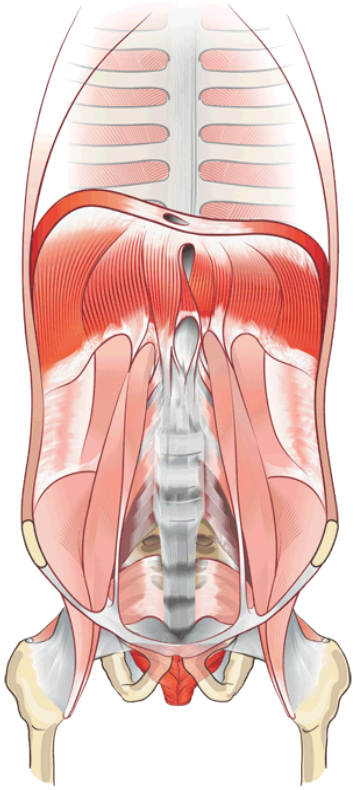

Illustration 17: core musculature
This is the core of CANTIENICA® muscle work: the inside of the body. The levator ani works as a shelf for the pelvis. The diaphragm takes the job of a shelf for the chest. Both shelves are connected via the iliacus and iliopsoas muscles as well as the deep back muscles and diaphragm muscle loop. Aligning and fully expanding all bones according to their original blueprint brings these two core muscle complexes into basic expansion. This makes the body responsive, strong, and flexible, and prevents typical age-related deformation.

With each breath, the diaphragm expands, strengthening its own muscles as well as the thoracic musculature deep within the chest.

Over the past few decades, there has been a veritable abdominal-breathing hype. In this idealized and often-preached breathing technique, the diaphragm is supposed to sink *down* with each *inhale* and lift back up during the exhale. When you do this, you automatically draw up the shoulders; the chest caves in; the abdominal and back muscles get shorter and thicker; the diaphragm presses down on the organs. There are training methods that tell explicitly to open up “the pelvic floor” to give the organs an escape route. If you are among those who learned this kind of abdominal breathing, unlearning it may be a challenge. But take heart! You have a wonderful feeling of lightness and some great beauty benefits to look forward to – they will more than make up for the effort.

CANTIENICA® breathing exercises aim to expand the diaphragm upwards and sideways with each inhale. This will strengthen the diaphragm muscles, keep the ribs and joints flexible, and increase the elasticity of the tendonous sheet. Trained and engaged this way, the diaphragm will also move upward when you laugh, cough, or sneeze – instead of pushing down onto the abdominal cavity. The sudden pressure increase is contained within the higher ribs and can’t wreak havoc below. This is crucial if you want to cure organ prolapse or incontinence.

Arms

In a vivatomically ideal posture, the humeral head is floating free below the acromion. The open joint cavity allows the arm full freedom of movement in all directions (a total of 12!). All the joints in the arm benefit from this freedom, including elbows, wrists, and finger joints. A healthy arm is always "in counter-rotation": at the wrist the muscles rotate inward, at the elbow outward; above the elbow the majority of muscles rotate inward, at the end of the arm the muscles rotate again outward, thus stretching the chest muscles. This counter-rotation ensures the arm's stability, strength, and flexibility.

Shoulders

A detailed vivatomical definition by Solveig Hoffmann, practicing physician and CANTIENICA® training instructor in Tenerife: "The shoulder is not a single joint (like knee or hip). It is a system of three bones: clavicle (collarbone), scapula (shoulder blade), and humerus (upper arm bone). These bones are connected through joints. The pectoral girdle (or shoulder girdle) consists of the two clavicles and the two shoulder blades. Between clavicle and shoulder blade on each side of the pectoral girdle are the two acromioclavicular joints, which serve as junctions between the two bones. Both clavicles are articulated with the sternum by the sternoclavicular joints. Humeral head and shoulder socket form a ball-and-socket joint – the term ‚shoulder join' commonly refers to this joint. According to conventional medicine, it is a ‚muscle-controlled' joint. The shoulder socket envelops only a small portion of the humeral head. It has an extension formed by a ring of cartilage. The joint is surrounded by the four rotator cuff muscles: subscapularis, supraspinatus, infraspinatus, and teres minor. They play a key role in controlling the joint."

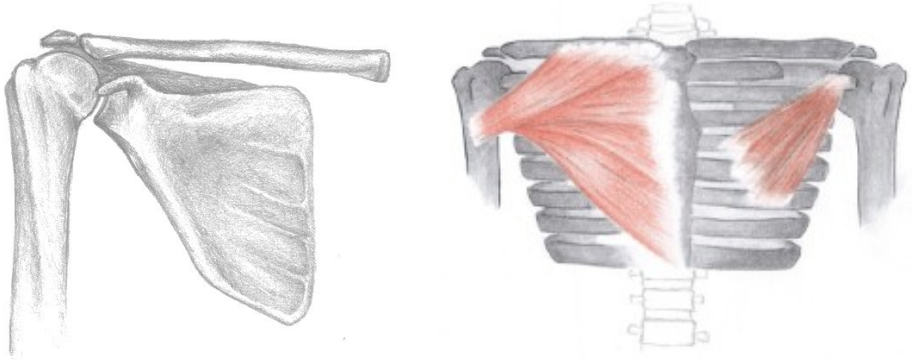

Illustration 18: Shoulder joint and Pectoralis muscles
The shoulder joint consists of the acromion, shoulder blade, and collarbone. Contrary to popular belief, the humeral head is not part of the shoulder joint. Sharing this misconception may likely lead you to pulling the humeral head up into the acromion, thus permanently (and painfully) twisting the "whole shoulder." The illustration to the right shows left the Pectoralis major and on the right the Pectoralis minor. It is the big team player for healthy shoulders and wide ribs. It assists the diaphragm and the rib-cartilages to expand and widen.

The CANTIENICA® Method lets shoulder and arm each do their own jobs. Unjammed from the acromion, the arm can just hang down and relax when inactive. Ideally, the shoulder blade is flat and aligned flush with the ribs – provided that the diaphragm is allowed its full radial expansion and doesn't get pushed down onto the abdomen.

Shoulders and arms have a unique idle condition. When the arm is inactive, the humeral head floats weightlessly on the outer edge of the horizontal ribs, resting until called up for duty – provided that the chest is fully expanded, that all vertical structures are equal in length, that all horizontal structures are equal in length. In this, the arms are unlike the rest of the body, which keeps actively erect and expanded along its central axis. The arms hang down, pulled down by their own weight. The double-stretch (downward and up) of the bones, tendons, ligaments, and muscles takes place without additional support. The more relaxed the arm, the more flexible its joints: finger joints, wrists, elbows, shoulder joints. If the humeral head is pulled or pushed up, the joint cavity between humeral head and acromion closes. This will create misalignment in the upper back; the shoulder blades move up; the large chest muscle (pectoralis major) constricts, and with it the latissimus dorsi. A vicious circle resulting in brick shoulders. If you treat "the shoulder" as a "muscle-controlled joint", you're in for more work than needed.

Now and again, there are drooping shoulders. This posture evolves when the torso lacks strength and expansion. Once the deep musculature is trained and engaged, the bones and joints of the shoulder return to their proper places.

Unlike the legs, pelvis, spine, and head, all of which stretch and erect to full expansion, the arm muscles should relax. The shoulders can just let go and relax – the acromion is free above the humeral head. This increases the arm's strength and flexibility and relieves all the joints. The collarbones are horizontal and level; the sternum is erect and long; the throat and neck muscles are naturally stretched – in front, at the back, and on the sides of the neck. The shoulder blades find their way to where they belong: snuggled flat against the back.

So here's what really happens when you "pull up the shoulders": almost invariably, you're pulling up the humeral heads, jamming them into the acromia, which are thereby forced into evasive action.

Legs

The human leg basically follows the same principle as the human arm: in the healthy, flexible leg, the head of the femur rests free in the acetabulum, and this freedom is not constrained during movement. The open joint cavity also ensures that the leg axis remains healthy: at the ankle the tibula has an inward-torsion. At the other end the bone rotates slightly outward. Same principle works for the upper thigh: The innate torsion goes inward above the knee and outward at the groin. This natural internal torsion keeps the legs virtually straight along the axis. Open hip joints grant freedom and width for the pelvic joints. The entire hip musculature thus aids the flexibility of the hip joints and pelvis. The knee benefits tremendously from this muscular bone alignment: it is relieved of all pressure and friction. The ankle, heel bone, and all the small joints of the foot are also unburdened.

Leg axis, counter-rotation

"Stretch the entire body up from the ground and hang it on its central axis": the right feet posture and an erect, expanded pelvis allow the body to align around its central axis. This brings the legs, too, into perfect axial alignment: the heels, knees, and hip joints are in a straight vertical line. In this posture, the leg muscles can achieve their ideal anatomical "counter-rotation". The leg muscles pull inwards at the ankle, outward just below the knee; the upper thigh rotates inward above the knee and outward at the end of the upper thigh (groin). This takes pressure and weight from the joints (knee, ankle, hip and sacral joints), stabilizes the leg axis, opens the groin, frees the psoas major, and gives strength to the "lever" that is the leg. If the legs lose the memory of this counter-rotation principle, they also lose their intended alignment. Leg deformities with all the consequential joint damages are the result: if all the leg muscles rotate outward, you'll be bowlegged (genu varum); if they all rotate inward, you'll get knock knees (genu valgum).

Illustration 19: Leg axis
The tibialis anterior muscle keeps the lower leg in rotation, the same going for the sartorial muscle with the upper thigh. This stylized drawing nicely illustrates the principle of counter-rotation. The lower leg bone turns inward directly at the ankle; "below the knee" it is straight. In contrast, the upper thigh bone is straight "above the knee" and turns outward with the upper thigh muscles at the top. In other words: the lower leg is rotated inward at the bottom; the upper thigh is rotated outward at the top.

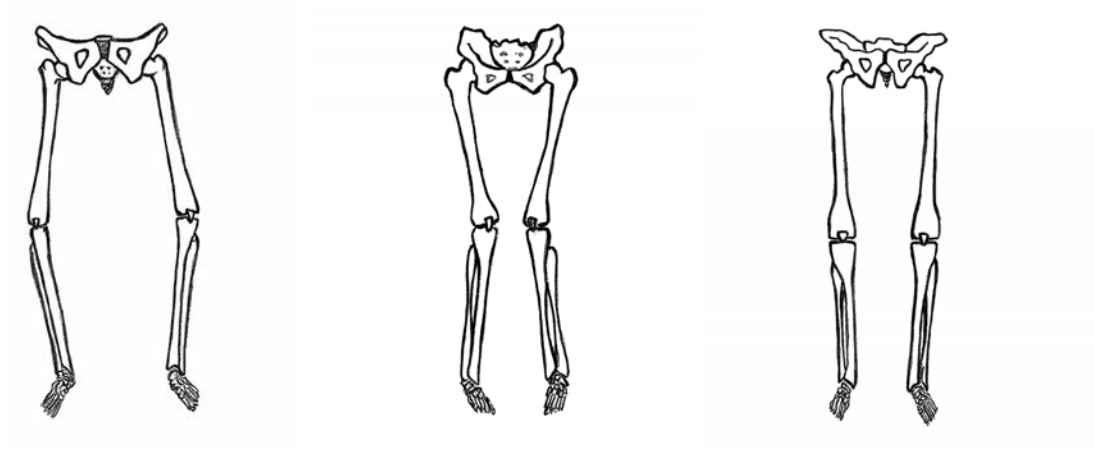

Illustration 20: Bowlegs and knock knees
Left: leg axis in a person with genu varum (bowlegs). Center: leg axis in a person with genu valgum (knock knees). Right: ideal leg axis.

Knees (hinge joints)

The knee is a simple hinge joint that is basically designed for two-dimensional movement, flexion and extension, back and forth. Every sideway movement or twist can damage the knee. To make it a bit more resilient, evolution provided it with a thick pad of cartilaginous tissue between the upper and lower leg: the meniscus. Strong ligaments at the front, the sides, and in the hollow of the knee also protect the knee. The CANTIENICA® Method relieves the knee joint in two ways: Firstly, by interconnecting of the entire pelvic floor musculature, you also interlink all the hip and leg muscles; secondly, the CANTIENICA®-exercises strengthen the muscles at the back of the leg while relieving and stretching the muscles at the front of the upper thigh. The knees benefit from both of these effects – even if you're an athlete.

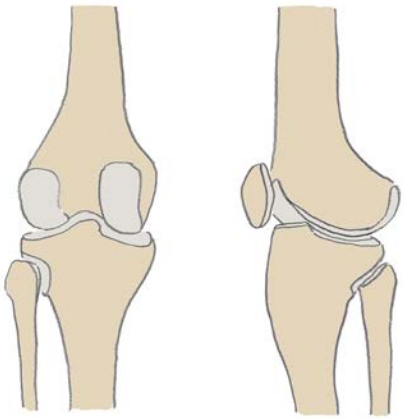

Illustration 21: Knee hinge joint
This is what it looks like when upper and lower legs are in perfect axial alignment. Each can move without damaging the other.

Foot posture

When the feet are in an vivatomically correct posture, the heels are always slightly closer together than the toes, wherever you're standing. The feet form a slight V.

If the feet are in this position – and only then – the pelvic bones, too, form a V: wide on top and narrow below. The deep muscles can establish their interconnections; the pelvic floor connects the upper thigh muscles to the muscular network of the torso. In this posture, the base of the big toe and the center of the heel are in active contact with the floor – light as a feather and ready to get moving at any time. The balls of the little and big toes are as close as possible forming the transverse arch; the medial longitudinal arch is drawn up slightly. This causes the fine musculature of the soles to connect and engage (adductor hallucis, caput transversum, flexor hallucis longis and brevis, flexor digitorum longus, etc.).

This foot posture is becoming increasingly common in yoga, qigong, and tai chi because it makes anatomical sense and prevents long-term damages caused for instance by an H- or A-shaped foot posture (damages that may occur include: bunions, flat feet, splayed feet, heel spur, knock knees, hip joints twisted inwards, pelvic misalignment, piriformis syndrome, ischiatic syndrome, lumbar disc herniation (slipped disc), facet joint syndrome, etc.).

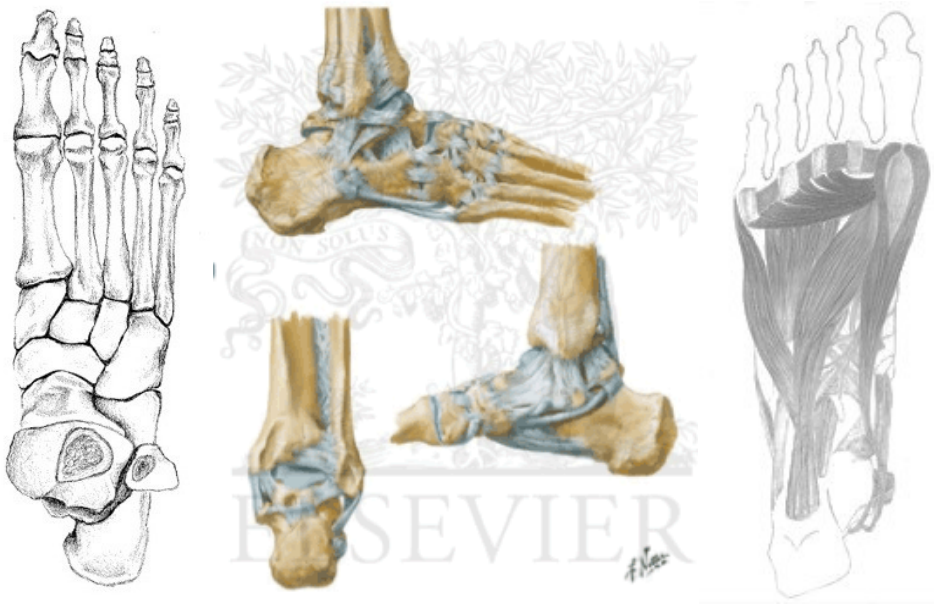

Illustration 22: The bones of the feet
Left: the bones of the feet.

Center: the ingenuous tendons that connect all the bones.

Right: the muscles at the soles of the feet. They connect everything else and are very often atrophied in adulthood.

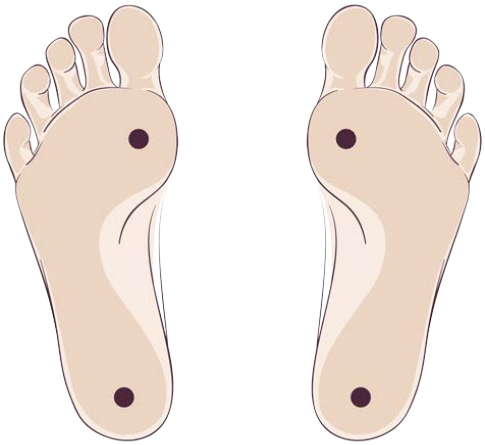

Illustration 23: Soles of the feet with contact points
The chain reaction that starts with the feet and continues through to the atlas joint and beyond will develop uninhibited if the feet are placed in their anatomically ideal V. The base of the big toe and the center of the heel are floating above the ground. This is deliberate! Anything exceeding a light floating would direct too much force into the ground. We want to be upright and erect, not bolted to the floor. Please notice: these two contact points underneath each foot are "floating melting points".

Longitudinal and transverse arches of the foot

The longitudinal arches of the healthy foot are supported by a dome-like system of muscles, tendons, and ligaments. In CANTIENICA® expansion the weight of the torso doesn't sink down because the body supports itself along its central axis, floating on the heels instead of pressing down onto the mid- or even forefeet.

The bases of the big and small toes are connected by an important muscle. This muscle, the caput transversum, is considered part of the adductor hallucis muscle. The active muscle support of the transverse arch prevents deformations like splayed feet as well as infections of the heel or the metatarsophalangeal articulations (the joints at the bases of the toes). A slackening of the caput transversum encourages the development of various hallux diseases. Like any musculature of the human body, the muscles in the sole of the foot can be deliberately and actively trained.

Covering the active transverse arches, lateral muscles, arranged in a V shape, run along the sole of the foot to the toes (abductor digitis minimi, abductor hallucis). The achilles' and patellar (knee) tendons link these muscles more or less directly to the leg, hip, and pelvic joints. With just a little help from the imagination, you can draw these two muscles toward the one in the center of the V (musculus flexor digitorum brevis). This tiny "motionless movement" has effects that continue at least through to the sitting bones, activating the levator ani – provided the feet are in their slight V position. If the feet are forming an H or even an A (as seen from above) there will be no chain reaction.

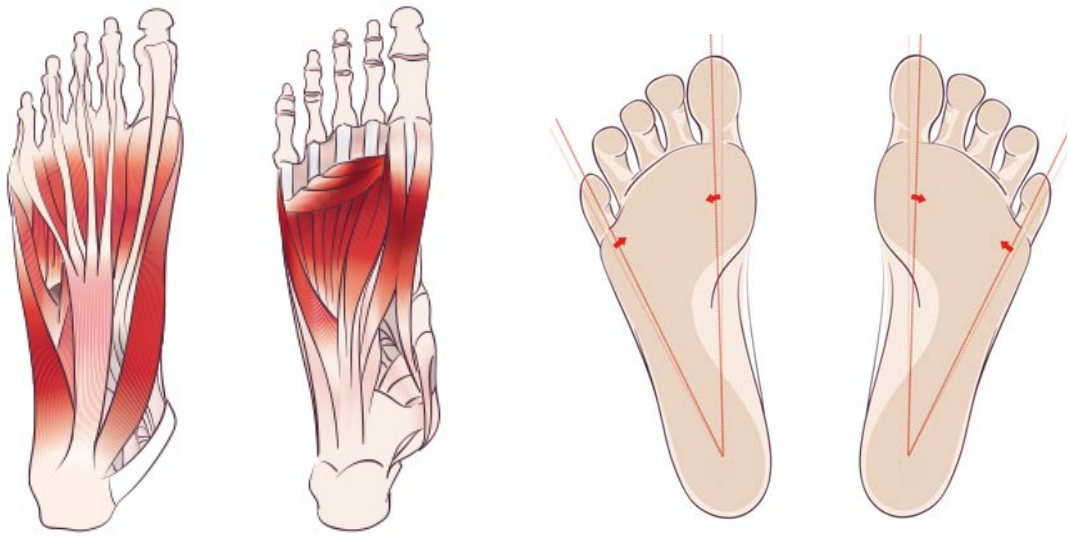

Illustration 24: Muscles at the soles of the feet
Left: the toe abductors, which are drawn together in the "V-in-V" foot position, initiating the chain reaction that continues through the pelvis.

Middle: the caput transversum. Traditionally considered part of the adductor hallucis muscle, it cushions the transverse arch of the foot. Without the power of the muscles, the bones of the feet have literally no hold – they deform.

Right: The action of the "V-in-V" foot position. The longitudinal tendons come closer together and, through this motion, activate and strengthen the arches of the foot.

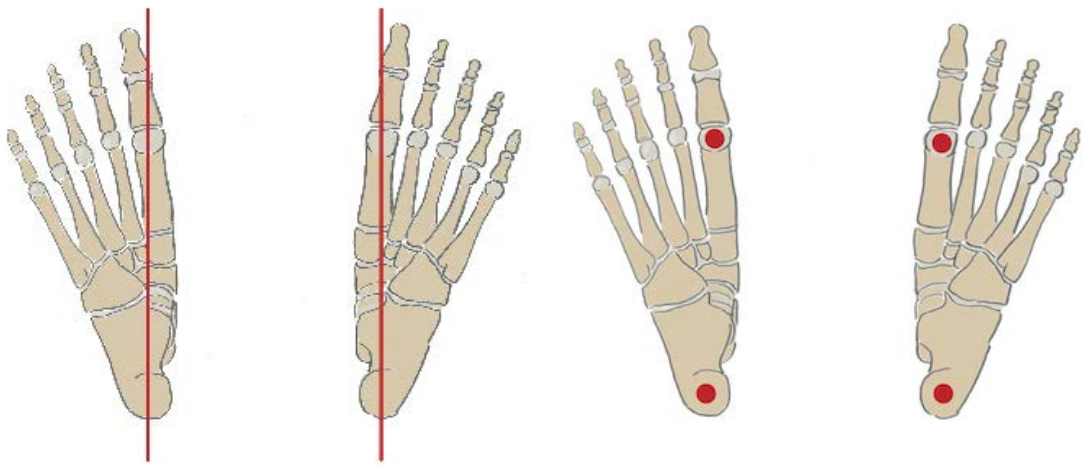

Left: The V-position oft he feet actually arranges the bones of the parallel, as illustrated by the vertical line. This enables the perfect array of the leg axis and results in free motion and mobility of the knees and the hip joints.

Right: The two red dots illustrate the points where the feet find solidity without pressure or strain. This spots are meant when the contact point of the feet are mentioned in the exercise instructions.